

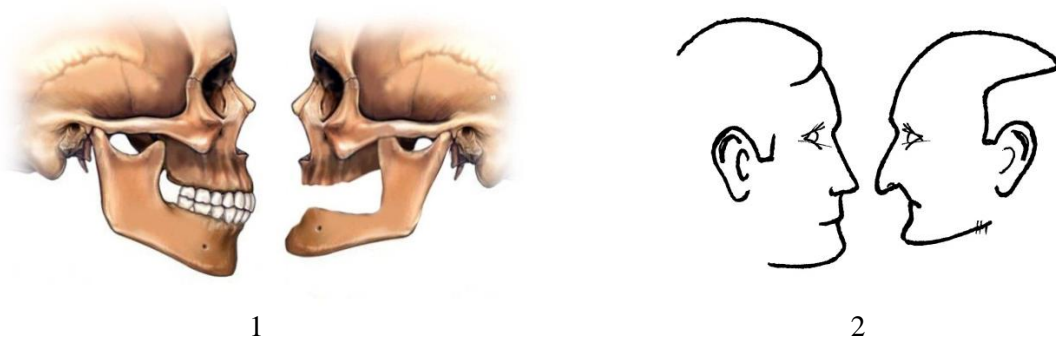**Lecture** “Partial dentures”. Part 4. Removable Partial Dentures. General characteristics of Complete Removable Dentures (full dentures). Construction of custom tray and wax bases with occlusal rims.

---

### ***General characteristics of Complete Removable Dentures (also Full Dentures)***

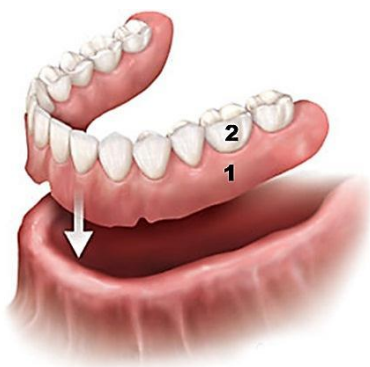Prosthetic treatment in totally edentulous patients is the most difficult kind of restorative treatment. There are a lot of individual changes that are usually occur after missing of all the teeth: changes in jaws (Fig. 1), masticatory muscles, temporomandibular joint (TMJ). It leads to disorders in chewing, speaking and breathing and also to changes in the topography and morphology of the soft tissues of the face. Loss of marks, which may help to determine the height of the lower portion of the face, shape and size of dentition, type of occlusion, makes the restorative treatment more difficult.

The success of treatment in toothless patients depends on the art of dentist, dental technician and on the laboratory equipment.



*Fig. 1. Changes in jaw bones (1) and face appearance (2) in edentulous patients.*

Complete Removable Dentures (CRD) are used in totally edentulous patients. CRD is a plastic base on denture – bearing area (Fig. 2.1) with artificial teeth which restore dentition (Fig. 2.2).



*Fig. 2. Complete Removable Denture of Lower Jaw: plastic base (1) and artificial teeth (2).*

For denture base fabricating polymethylmethacrylate resins (heat – cured, self – cured and light cured) and thermoplastic resins (for injection molding) are used (see the topic “Polymers materials used in dentistry”).

To restore a dentition in CRD porcelain and acrylic artificial teeth are used.

**Lecture** “Partial dentures”. Part 4. Removable Partial Dentures. General characteristics of Complete Removable Dentures (full dentures). Construction of custom tray and wax bases with occlusal rims.

### Laboratory processing route of CRD fabricating.

CRD manufacturing in edentulous patients includes the following clinical and laboratory steps.

№	CLINICAL steps	LABORATORY steps	№
1	<i>Patient examination, treatment plan, primary impression</i>		
		<b>Gypsum model (primary) pouring, custom tray fabrication</b>	<b>1</b>
2	<i>Try – in of custom tray, Making of functional impression</i>		
		<ul style="list-style-type: none"> <li>• <b>Boxing - in of impression</b></li> <li>• <b>Pouring of master cast</b></li> <li>• <b>Wax bases with occlusal rims constructing</b></li> </ul>	<b>2</b>
3	<i>Establishment of centric jaw relation</i>		
		<ul style="list-style-type: none"> <li>• <b>Articulating models;</b></li> <li>• <b>Setting up of artificial teeth</b></li> </ul>	<b>3</b>
4	<i>Preliminary insertion of complete denture wax up (trial denture)</i>		
		<ul style="list-style-type: none"> <li>• <b>Final modelling of CRD;</b></li> <li>• <b>Replacement wax with acrylic resin;</b></li> <li>• <b>CRD grinding and polishing</b></li> </ul>	<b>4</b>
5	<i>CRD insertion in patient’s mouth, control of quality and function. Providing advice on the use of denture.</i>		

### ***Pouring a gypsum models and constructing of custom trays.***

Dental technician on the primary model fabricates custom tray (individualized trays or Tailor made trays). Custom trays are made on primary (study) models and provide an accurate foundation for making the final (secondary) impression from which the master casts are constructed. Accurate recording of the functional sulcus is essential to define the denture extension and resulting retention and stability. Retention depends on the denture extending to fill the sulcus and thus creating a seal.

For custom tray fabrication self – cured (or cold – cured), light – cured acrylic resins, shellac base plates, standard prefabricated blanks (polystyrol) for thermovacuum forming (see the topic “Polymers materials used in dentistry”).

Dental technician on a primary (study, diagnostic) model marks with indelible pencil the estimated borders (Fig. 3). For borders marking on vestibular surface oral vestibule is used as landmark (oral vestibule exists between the lips and cheeks and the alveolar ridge). The position of the periphery of the tray should finish 2 mm short of vestibule (sulcus and muscles attachments). In position of lip and buccal frenums it should finish 3 mm short. In distal parts of upper jaw the vestibule part of custom tray transfers to distal border. In upper jaw it should cover maxillary tuberosities and extends 2 mm beyond the foveae palatine. For the mandible the distal the vestibular part transfers to lingual part including retromolar pad.

**Lecture** “Partial dentures”. Part 4. Removable Partial Dentures. General characteristics of Complete Removable Dentures (full dentures). Construction of custom tray and wax bases with occlusal rims.

From lingual surface the periphery border should finish 2 mm short of the floor of the mouth. It should also avoid lingual frenum.



Fig. 3. Periphery borders of custom trays marked on upper jaw (1) and lower jaw (2) study models

For custom trays fabricating the following materials and techniques are used (in Table)

Table. Polymer materials and techniques that are used for custom tray fabricating.

<i>Materials</i>	<i>Technology</i>
PMMA cold - cured (self – cured)	Adapting Technique
	Sprinkle on Technique
Light - cured	Adapting Technique
Shellac thermoplastic materials	
thermoplastic materials (polypropylene, polychlorvinyl, polycarbonate, polyethylene terephthalate)	Thermovacuum forming and thermoforming under pressure

The processing route of custom tray fabricating was described in the lecture “Technological processes used in denture fabricating from polymer materials”.

For dentist’s convenient use it is necessary for custom tray to have a handle. During handle construction it is very important to determine its shape and position. Incorrect handle can reduce the quality of impression (because of custom tray displacement during impression taking) (Fig. 4)



Fig. 4. Position of the handle of maxillary custom tray towards the lip: incorrect (1), correct (2)

In mandibular custom tray it is also desirable to make two finger stops in the area of the missed first premolars (Fig.5).

**Lecture** “Partial dentures”. Part 4. Removable Partial Dentures. General characteristics of Complete Removable Dentures (full dentures). Construction of custom tray and wax bases with occlusal rims.

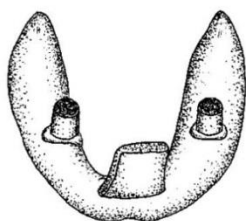


Fig. 5. Maxillary custom tray

**Boxing – in the custom trays, pouring working models, constructing of the wax bases with occlusal rims.**

Working models (or master models) are produced from the working (or secondary) impressions. To save the shape of the impression periphery that reproduces the condition of the movable mucosa with its function it is possible to make boxing – in. For boxing – in the wax strips with thickness of 2 mm and width of 5 – 6 mm. are used.

In upper impression the wax strips are attached to distal and vestibular surfaces leaving about 3 mm. of the sulcus showing (Fig. 6.1). In lower impression boxing in is made in vestibular and lingual surfaces 2-3 mm below the impression border (Fig. 6.2).

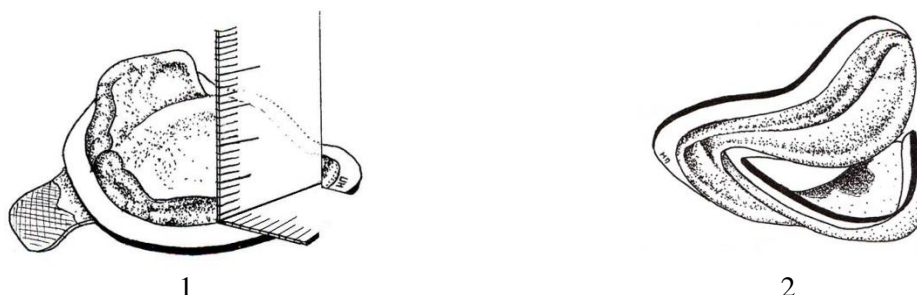


Fig. 6. Boxing - in of the final impressions of lower (1) and upper (2) jaws

During model producing boxing - in helps to save the periphery of the impression. It will promote a good peripheral seal and suggest a good fit of the future finished denture.

After boxing – in dental technician pours a master model. For master (working) model  $\alpha$ -modification of gypsum is used (dental stone or Kaffer D). The base of the model should be approximately 12-16 mm high. It is necessary to trim the periphery of the model in order to protect the model surface from the chips in this area and to ease the wax base removing (Fig. 7.2).

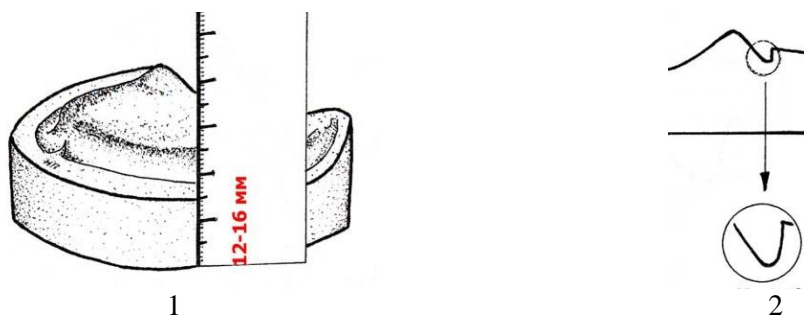


Fig. 7. The height of the model's base (1) and correction of the model periphery (2) that reproduces a seal area

**Lecture** “Partial dentures”. Part 4. Removable Partial Dentures. General characteristics of Complete Removable Dentures (full dentures). Construction of custom tray and wax bases with occlusal rims.

For wax bases with occlusal rims constructing baseplate (or modeling) is was used (Fig. 8.1).



Fig. 8. Baseplate wax for wax bases (1) and prefabricated occlusal rims(2)

A piece of modeling wax, sufficient to cover the cast is softened over a spirit lamp only in one surface without melting of the wax. Heated surface is then adapted carefully to the surface of the cast. Excessive wax is cut with heated spatula (according to the borders of neutral area that are reproduced in final impression). Occlusal rims can be also done from baseplate wax. To make occlusal rims dental technician softs the sheet of baseplate wax in both surfaces over flame until pliable condition, then tightly rolls it into a rod, bends this rod to the approximate shape of arch form of either maxillae or mandible. It is again softened and adapted to the alveolar ridge area of the wax base. Place the occlusal rim onto the surface of a glass slab with cast looking up. Compress the wax rims keeping the cast surface parallel to the glass surface. After this procedure occlusal rim becomes square shape in its cross – section (Kopeikin V.N., 1985).

For ocllusal (bite), rims constructing prefabricated samples can be used (Fig. 8.2). These rims are attached to the wax base with molten sticky wax. The height of occlusal rims in patients with average degree of bone resorption is 18-22 mm, the width in frontal region – 3-5 mm, in distal regions – 8-10 mm (Fig. 9.1).

All the surfaces of occlusal rims should be smooth and should be beveled in vertical plane in approximately  $10^{\circ}$ . In distal regions the bevel should be  $45^{\circ}$  (Fig. 9.2).

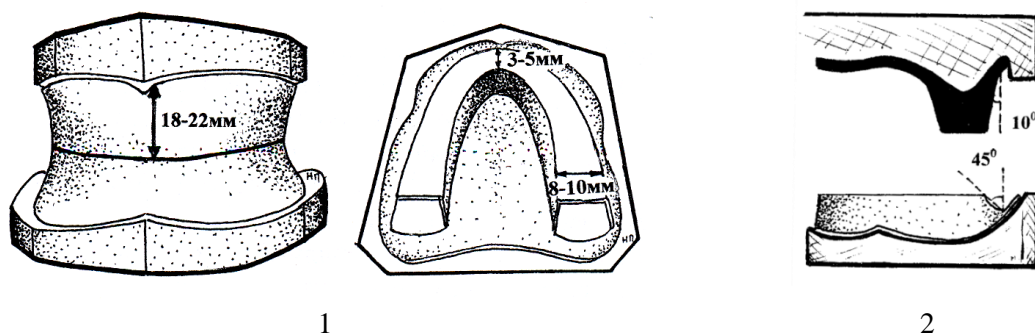


Fig. 9. Occlusal rims measurements in average degree of bone resorption (1) and making bevels (2)

To create the ideal shape of occlusal rims without a flame special electric device – Naishe apparatus - can be used. In this device sloping metal plate heats the wax and causes its melting.

**Lecture** “Partial dentures”. Part 4. Removable Partial Dentures. General characteristics of Complete Removable Dentures (full dentures). Construction of custom tray and wax bases with occlusal rims.

---

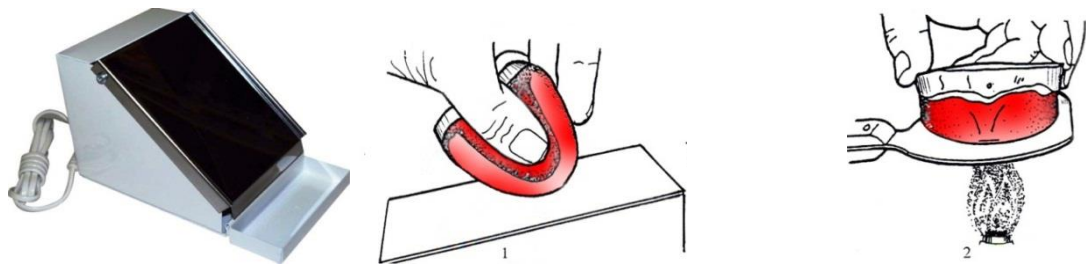


Fig. 10. Occlusal rim forming with Naishe apparatus (1) and with metal plate by heating with flame (2)

The process of positioning teeth on a base is termed setting up. Its purpose to improve or restore masticatory efficiency, to restore speech and to restore or improve the patient's appearance.

The most popular method of denture teeth setting up in former Soviet Union countries was the method developed by Vasiliev M.R. (denture setting up with glass slab). This method allows to create sagittal and transversal occlusal curvatures.

But this method cannot be used in the most cases because the anatomical denture teeth setting up can be provided only in patients with orthognathic bite type with little jaw bone resorption (loss). If follow the rule of denture teeth positioning on the crest of the alveolar processes which have jaw bone loss, the created artificial dentition will be different in its shape and size than natural dentition before teeth loss (Kalinina N.V., Zagorskii V.A., 1990).

Denture teeth setting up with use of constant anatomical landmarks allows to restore not only teeth but also lost alveolar bone, to reproduce face configuration that existed before the loss of the teeth (Buhal et al., 1991).

For denture teeth positioning the following anatomical landmarks of edentulous jaws are used (Fig. 1).

**Incisal papillae.** In the middle line of the upper jaw, distally to the alveolar ridge incisal (incisive) papillae is located (Fig. 1.1). It is a small tubercle, overlies the incisive foramen, through which the incisive nerve and blood vessels exist. The incisal papillae is a good landmark of midline and used during positioning of upper central incisors and canines.

**Midsagittal line.** Midsagittal line (Fig.1.3) corresponds to the esthetic face center. To mark midsagittal line it is not desirable to use lip frenulum as landmark because of its possible abnormal position. In upper jaw midsagittal line passes through the incisive papillae and fovea palatine. To mark midsagittal line in mandible equilateral triangle is used. Its base is the distance between retromolar pads (Fig. 1.5). The sagittal line passes through the middle of the base of an equilateral triangle and its top.

**Palatine rugae.** They extend bilaterally from the midline in the mesial third of hard palate. The number is from three to six on each side. Frontal pair of palatine rugae (Fig. 1.2) is a landmark of canines' position.

**Fovea palatini.** The fovea palatine are two depressions that locate in distal part of hard palate, at the approximate junction between the soft and hard palate. They are often useful in determination of the distal denture border and they help to detect the midsagittal line.

**Maxillary tuberosity.** The maxillary tuberosity (Fig. 1.5) is the most posterior part of the alveolar ridge; it lies distal to the position of the last molar. It is the bulbous mass of mucous

**Lecture** “Partial dentures”. Part 4. Removable Partial Dentures. General characteristics of Complete Removable Dentures (full dentures). Construction of custom tray and wax bases with occlusal rims.

membrane that overlies a bony tuberosity. Their marking on gypsum models helps to dental technician to determine the distal denture border.

**Alveolar line.** Alveolar ridges cannot serve as landmarks for denture teeth setting up because of atrophy changes their shape and the size. To restore esthetic and function in edentulous patients it is necessary for denture base and artificial teeth to reproduce the lost patients’ structures that existed before teeth and jaw bone loss (Kalinina N.V., Zagorskii V.A., 1990). The alveolar line (Fig. 1.4) helps to determine the highest point of retromolar pad.

**Retromolar pad.** In the lower jaw, a triangular area of thick mucosa is found distal to the last molar, basically on the crest of the ridge, and is referred to as the retromolar pad (Fig. 1.7). In this retromolar pad after third molar extraction the mandibular tubercle locates. The retromolar pad should be covered by the denture.

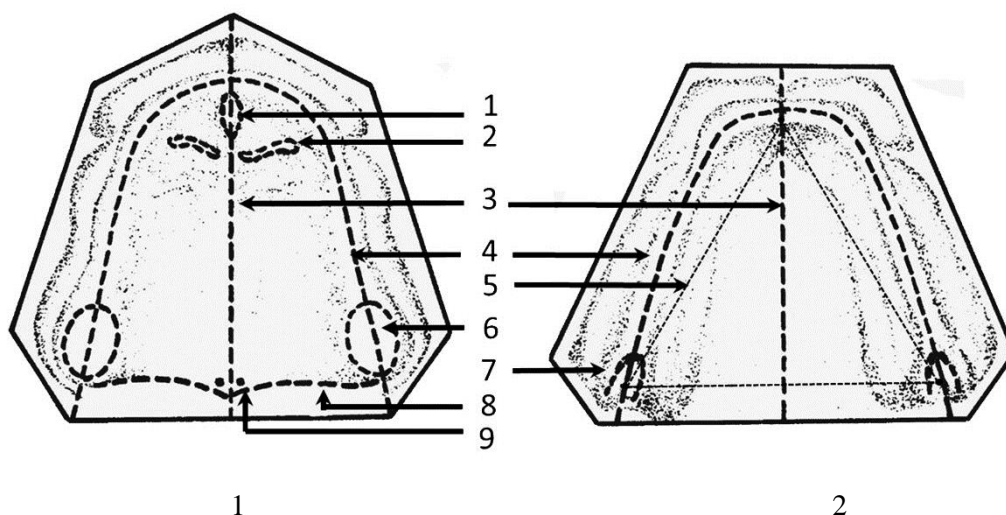


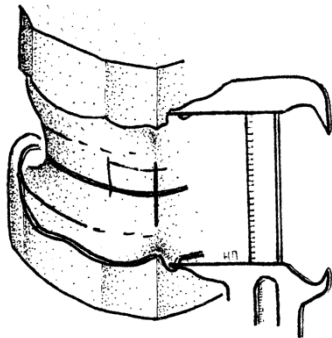
Fig. 1. Anatomical landmarks on the upper (1) and lower edentulous jaws (2) used for denture teeth setting up.

When setting the teeth, first upper central incisors are placed. The incisal edges position is determined on the vestibule size. On the gypsum models that are fixed on articulator dental technician measures **FF** distance with ruler or with caliper (FF distance is the distance between two points that are below upper and lower lips frenulums).

The incisal edge of upper central incisors should lie at the level of incisal point **i**, which in orthognathic jaw relationship locates 2 mm below the half of the size of the vestibule of the oral cavity. The position of incisal edge is determined by formula:

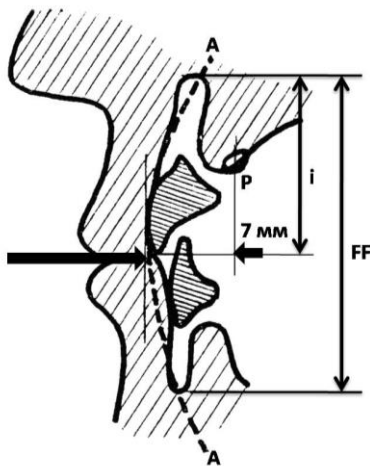
$$i = (FF : 2) + 2 \text{ mm}$$

**Lecture** “Partial dentures”. Part 4. Removable Partial Dentures. General characteristics of Complete Removable Dentures (full dentures). Construction of custom tray and wax bases with occlusal rims.



*Fig. 2. Determination of vestibule size*

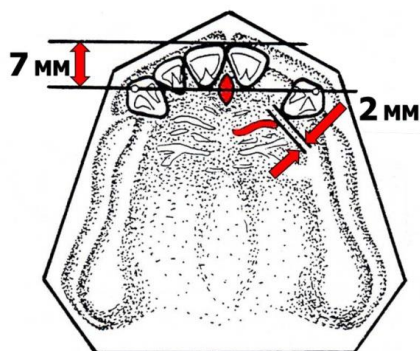
Besides that the labial (vestibular) surfaces of central incisors should fit harmoniously into the contours of the vertical frontal arc (AA) being a part of it (Fig. 3)



*Fig. 3. Position of central incisors in relation to the size of vestibule of oral cavity (FF), incisal point (i), vertical frontal arch (AA) and incisal pappilae (P)*

According to different authors recommendations artificial central incisors should be placed anteriorly to incisal papillae at a distance of 7 mm (Fig. 3, fig. 4).

The main landmarks for the canine positioning are palatine rugae. Canines are placed with axial tilt in mesial side at a distance of 2 mm from a palatine rugae (Fig. 4). The neck of the canine should be prominent and more anteriorly placed than the incisal edge to emphasize the canine eminence and to support the lips. Incisal papillae also can be used as a landmark for canine positioning. According to S.Schiffman (1964) the line that connects the tips of canines usually passes through the middle of incisal papillae in 68 % of the patients. (Fig. 4).



*Fig. 4. Upper frontal teeth position in relation to palatal rugae and incisal papillae.*

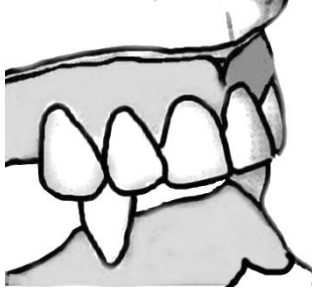


**Lecture** “Partial dentures”. Part 4. Removable Partial Dentures. General characteristics of Complete Removable Dentures (full dentures). Construction of custom tray and wax bases with occlusal rims.

---

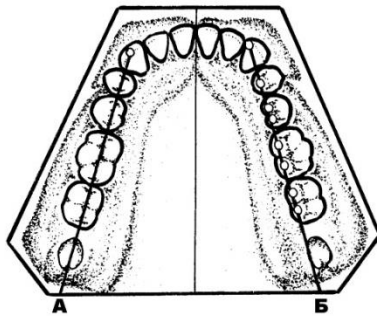
Lateral incisors are placed between the canines and central incisors. Their incisal edge should be 0,5 mm off the occlusal plane with little mesial inclination of the long tooth axis.

After setting up of upper frontal teeth, lower canines are positioned. Lower canines are set in the corresponding neutral bite position relative to the upper teeth (between the lateral incisor and the canine) with mesial inclination (Fig.5).



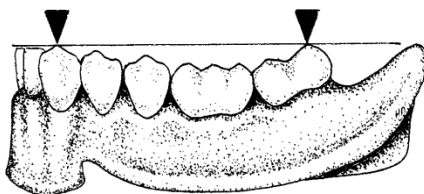
*Fig. 5. Setting up of lower incisors.*

Position of posterior lower teeth is determined with alveolar line (Fig. 6A). The central fissures of posterior teeth are matched with alveolar line. In addition for posterior lower teeth setting up a Pound's line is used (E.Pound, 1957). This line passes through the lingual cusps of posterior teeth from mesial ridge of canine to lingual border of retromolar triangular (Fig. 6B).



*Fig. 6. Setting up of posterior lower teeth using alveolar line position (A) and Pound's line (B)*

Compensating curvature of Spee (occlusal curvature in saggital plane) is formed relative to the line which is passed from the tip of lower canine (line of lips closing) to the middle of retromolar triangle (Fig. 7). This curvature is formed because the first premolar locates 0,5 mm below the canine's cusp, the second premolar – 0,5 mm below the first premolar, the first molar - 0,5 mm below the second premolar and the second molar's distal buccal cusp is in contact with this plane.




*Fig. 7. Occlusal curvature formation during lower posterior teeth setting up*

After setting up of lower posterior teeth, upper posterior teeth are positioned. In upper posterior teeth setting up the position of lower posterior teeth serves as a landmark (Fig. 8.1).

**Lecture** “Partial dentures”. Part 4. Removable Partial Dentures. General characteristics of Complete Removable Dentures (full dentures). Construction of custom tray and wax bases with occlusal rims.

---

The vestibular surfaces of the canines and molars touch a straight line, to which premolars are located (Fig. 8.2).



*Fig 8. Setting up of posterior teeth of the upper and lower jaws.*

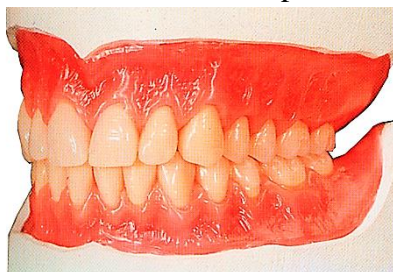
The lower incisors are last to be positioned. Lower anterior teeth should be positioned to create an arbitrary 1–2 mm overjet and overbite where possible.

After setting up of artificial teeth dental technician starts to model the denture base surface. The waxed denture pattern should have the same thickness and relief as future denture. The denture base should be extended fully into the sulcus to achieve a good seal between the denture periphery and the tissues. Sculpting the wax around the teeth can affect esthetics and hygiene. The gingival area should be sculptured to create as an aesthetic and natural situation as possible.

The upper waxed denture pattern should have the uniform thickness throughout. The palate should generally be smooth and extend to the junction of the hard and soft palate. The shape of the anterior palate can have a significant effect on speech. The formed rugae should be smooth so they do not irritate the tongue, collect food debris or encourage plaque accumulation.

Lower denture base is usually thicker than upper one. The lingual surface in frontal teeth area is made slightly bended for a free fit and movement of the tip of the tongue. In the area of posterior teeth bends are formed in middle parts for lateral tongue surfaces location.

The final step of waxed denture pattern modelling is its attachment to the working models. To do this over the flame of a spirit lamp or gas burner the wax is melted on the spatula and then poured the basis around the perimeter of its borders with the gypsum model (Fig. 9).



*Fig. 9. Waxed denture bases of CRD after final modelling and attachment to the gypsum model.*

After final modelling it is necessary to replace wax with acrylic resins. The ways of replacement are shown on Fig. 10.

**Lecture** “Partial dentures”. Part 4. Removable Partial Dentures. General characteristics of Complete Removable Dentures (full dentures). Construction of custom tray and wax bases with occlusal rims.

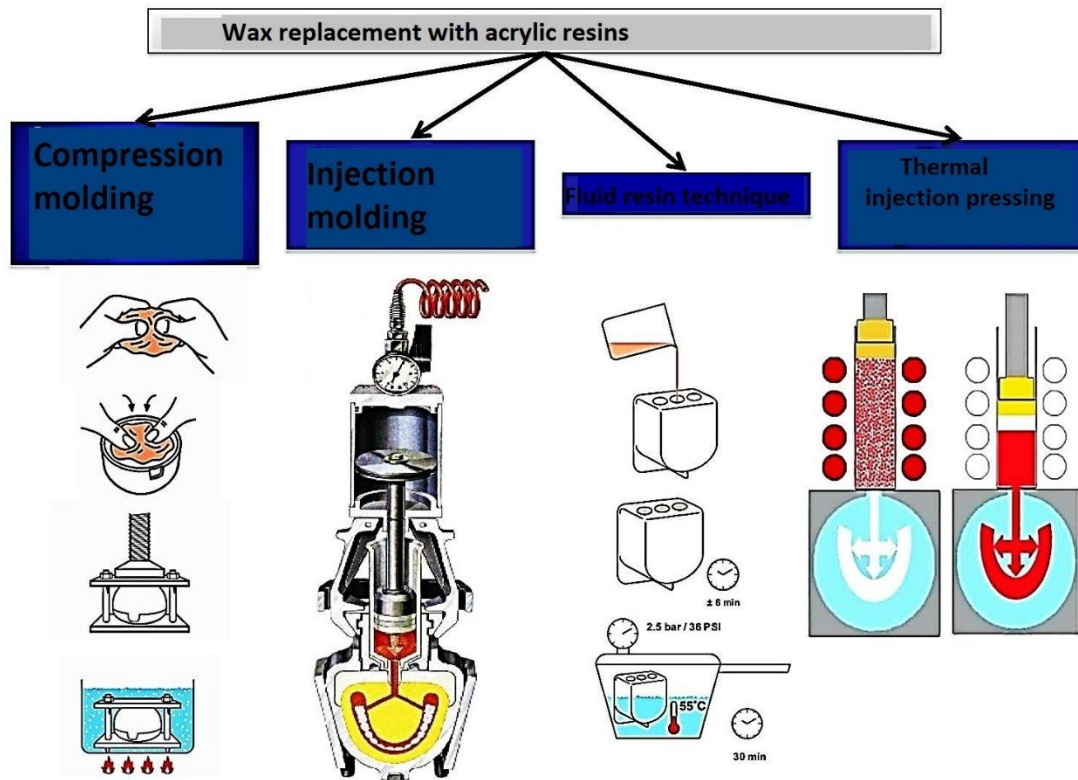


Fig. 10. The ways of wax replacement with acrylic resins.

After acrylic resin polymerization and deflasking (the procedure of removing a denture from its embedded plaster) dental technician does finishing procedures. The finishing of the denture consists of the following procedures: shaping – smoothing – polishing.

At first it is necessary to remove excess plastic and rough edges. For this procedure rotary abrasive instruments are used. But the inner (fitting) surface is not shaped in order to prevent the damage of its matching to denture – bearing area.

After shaping the surface of denture is smoothed with sandpaper. Firstly the rough sandpaper (large grain size of abrasive material) is used, then more subtle (with a fine grain size of abrasive).

The final procedure is polishing. It consists of smoothing by use of a mild abrasive (such a pumice) followed by the formation of a highly glossed surface.

For polishing brushes of different size and shapes, soft wool mop, canvas buff wheels, etc. can be used.

### **Possible processing problems during injection molding and compression molding techniques.**

Because of different mistakes during denture processing it is possible to make various defects: porosity (gaseous, granular, because of insufficient compression), inner stress and cracks.

*Gaseous porosity* appears as voids and bubbles within the mass of the polymerized acrylic. It is caused by the boiling of monomer, particularly if too much has been added to the dough

**Lecture** "Partial dentures". Part 4. Removable Partial Dentures. General characteristics of Complete Removable Dentures (full dentures). Construction of custom tray and wax bases with occlusal rims.

---

or if the temperature is raised too quickly, causing the exothermic curing reaction to generate temperature rises above the boiling point of monomer (100,3 °C).

This potential problem can be eliminated by having a long curing period with a hold period at about 70°C, to allow too exothermic reaction within the processing flask to pass, before increasing the temperature for final processing (95°C).

*Granular porosity* occurs when the wrong ratio of powder and liquid during the preparation of the plastic dough and the evaporation of the monomer. If the dough is not homogenous at the time of polymerization, the portions containing more monomer will shrink more. This localized shrinkage results in voids. The resin appears white. Avoided by using proper powder/liquid ratio and mixing it well. The mix is more homogenous in the dough stage, so packing should be done in the dough stage. It is also necessary to place a lid on the vessel with acrylic mass in order to prevent evaporation of the monomer.

*Porosity because of the lack of adequate pressure.* Lack of pressure during polymerization or inadequate amount of dough in the mold during final closure causes bubbles which are not spherical. The resin is lighter in color. Avoided by using the required amount of dough. Check for excess or flash during trail closure. Flash indicates adequate material.

*Crazing* is formation of surface cracks on the denture base resin. The cracks may be microscopic or macroscopic in size. In some cases it has a hazy or foggy appearance rather than cracks. Crazing weakens the resin and reduces the esthetic qualities. The cracks formed can cause fracture.

Causes: Crazing is due to:

1. Mechanical stresses or
2. Attack by a solvent
3. Incorporation of water

In poly (methyl methacrylate) crazing occurs when tensile stresses are present. The cracks are at right angles to the direction of tensile stress. Crazing is a mechanical separation of the polymer chains or groups under tensile stress.

Crazing is visible around the porcelain teeth in the denture and is due to the contraction of the resin around the porcelain teeth during cooling after processing.

Weak solvents like alcohol result in randomly placed cracks. Water incorporation during processing will form stresses due to evaporation of water after processing, causing crazing.

Avoided by

1. Using cross linked acrylics
2. Tin foil separating medium
3. Metal molds

*Denture warpage* .Denture warpage is the deformity or change of shape of the denture which can affect the fit of the denture. Warpage can occur during processing as well as at other times. It is caused by a release of stresses incorporated during processing. Some of the stresses are incorporated as a result of the curing shrinkage while other stresses may be a result of the uneven or rapid cooling. Packing of the resin during the rubbery stage can also

**Lecture** “Partial dentures”. Part 4. Removable Partial Dentures. General characteristics of Complete Removable Dentures (full dentures). Construction of custom tray and wax bases with occlusal rims.

---

induce stresses. Some stresses may be incorporated during improper deflasking. These stresses are released subsequently:

- During polishing, a rise in temperature can cause warpage
- Immersion of the denture in hot water can cause warpage
- Re-curing of the denture after addition of relining material, etc.