

A Clinical Overview of Removable Prosthodontics: 2. Impression Making for Partial Dentures

J. FRASER McCORD, NICK J.A. GREY, RAYMOND B. WINSTANLEY AND ANTHONY JOHNSON

Abstract: This, the second article in a series on the prescription of removable partial dentures, will deal with the issue of primary impressions and primary casts for partial dentures. The principles of definitive impressions and master cast planning will be described.

Dent Update 2002; 29: 422–427

Clinical Relevance: This article outlines how to select a stock tray, how to customize a stock tray, if required, how to plan special trays and which impression technique to use.

The keystone of clinical dentistry, in whichever specialty, is sound diagnosis and treatment planning. This often involves measured contemplation of the case in the absence of the patient, but with clinical data at hand. This indirect planning will involve articulated study casts and radiographs. Although the treatment chosen may not involve the use of partial dentures, in this article we discuss the issue of primary impressions and casts.

PRIMARY IMPRESSION MAKING

The function of all primary impressions

J. Fraser McCord, BDS, DDS, FDS, DRD RCS(Edin.), FDS RCS(Eng.), CBiol, MIBiol, Professor and Head of Unit of Prosthodontics, University Dental Hospital of Manchester; **Nick J.A. Grey**, BDS, MDS, PhD, FDS, DRD, MRD RCS(Edin.), Consultant/Honorary Senior Lecturer in Restorative Dentistry, Edinburgh Dental Institute; **Raymond B. Winstanley**, BDS, MDS, FDS RCS(Edin.), Senior Lecturer/Honorary Consultant in Restorative Dentistry, Charles Clifford Dental School, Sheffield; and **Anthony Johnson**, MMedSci, PhD, Lecturer in Dental Technology, Charles Clifford Dental School, Sheffield.

for removable prostheses is to record the denture-bearing area; this involves comprehensive recording of all teeth, the ridges in those spans where there are missing teeth and the palate.

To achieve this, clinicians tend to use what are termed 'stock trays', of which a variety is available. These stock trays vary in quality and price and may be made of flexible or more rigid plastic or metal. Most may be used to record moderate-sized dentate arches, but for large edentulous areas the clinician may have to select a specific form of stock tray or modify the tray to suit the clinical situation.

We deprecate the philosophy held by some clinicians that 'it's just first impressions': high-quality treatment begins with a thorough diagnosis and treatment planning and continues with all stages of prosthodontics. There is no doubt that most technicians are able to gauge a clinician's clinical ability on the basis of their impressions and primary impressions are no exception.

In this article, we describe three impression-making techniques:

1. The 'conventional' type, where

small saddles exist.

2. The technique for dealing with larger saddles or where, for example, a large saddle(s) are found or the patient has a deep palate and the stock tray is of a conventional form.
3. The technique used for a patient with bilateral free-end saddles when a stock tray must be made specifically for the purpose.

1. Technique for Conventional Impressions

Any of the stock tray types may be used, on the condition that the tray selected mirrors the width, depth and length of the arch being replicated. One variety we find very useful because of its range of sizes and variety of forms is that made by Schreinemaker (Clan, Maarheeze, The Netherlands) (Figure 1).

The impression material used is usually irreversible hydrocolloid, although this is not essential and is entirely a matter of clinician preference. We strongly recommend that the opposing arch is also recorded. Depending on the number and position of teeth present in both arches, an intermaxillary record may be necessary to enable articulation of the primary casts, in order that the clinician may assess the situation, contemplate the patient-related factors and decide upon the design of the prosthesis. (It is assumed that acceptable clinical practice such as application of adhesive, mixing of impression material, impression technique and infection control practice are carried out).



Figure 1. Examples of one of the more reliable makes of maxillary and mandibular metal stock trays.

2. Technique for Larger Saddles or Deep Palate

In such a situation, the tray selected may have sufficient length and width, but the depth tends to be insufficient to guarantee acceptable and comfortable seating of the tray or predictable results. For this reason, there is sense in customizing the tray (we prefer in this instance to select a metal tray) with an intermediate material; we tend to favour an impression compound material (Figure 2). A variety of compound products is available: our preference is Cameo (Cottrill Ltd., Feltham, Middlesex, UK), which softens at a lower temperature than others and exhibits sufficient elasticity at mouth temperature to enable removal from small dental undercuts. Once the tray has been customized to ensure stable seating onto the denture-bearing areas, an overall impression in, for example, irreversible hydrocolloid may be recorded (Figure 2). An additional advantage of this technique is that less impression material is required and, further, there will in consequence be less likelihood to induce retching by the patient. In conventional techniques, excessive loading of the tray with, for example, irreversible hydrocolloid to fill the vault of the

palate may result in the impression material flowing into the oropharynx.

The opposing arch may then be recorded and, if required, the appropriate intermaxillary registration taken. If many teeth are missing, it might not be possible to reproduce the desired jaw relationship (on the casts) and occlusal rims will be needed before the casts can be articulated with accuracy relative to the intra-oral occlusion. This will be discussed later.

3. Technique for Bilateral Free-end Saddles Using a Specially Designed Stock Tray

In our experience, use of conventional 'box' trays enclosing irreversible hydrocolloid impression material alone

rarely results in acceptable impressions in unilateral and bilateral free-end saddle cases. The tray may be customized with, for example, Cameo perfectly satisfactorily (Figure 3) but good results are also obtained when trays specifically designed for this clinical scenario are used.

An example is the tray made by Inox (Schwert, Postfach 69, D78501 Tuttlingen, Germany), which may be 'customized' in tracing compound before recording the entire arch with (e.g.) irreversible hydrocolloid (Figure 4). Depending on the number and distribution of teeth remaining, it may be possible to articulate the resultant cast and its opposing cast; alternatively, registration rims may be required.

PRIMARY CAST AND PRE-DEFINITIVE CLINICAL PROCEDURES

This area tends to receive scant attention yet it is an important part of the design and impression-making component of partial denture provision.

Clearly, as primary impressions should be of acceptable quality to record the denture-bearing areas and to facilitate design, the primary cast should also be good enough to enable subsequent unambiguous articulation of casts. Thus the forms and contours (especially the occlusal contours) should faithfully reproduce the teeth being recorded. Equally, heels of casts should not interfere with the articulation of the upper and lower casts.




Figure 2. (a) Cameo compound has been added to the stock tray to provide a more customized tray, and one that will be more stable during the recording of the impression. (b) The completed primary impression.

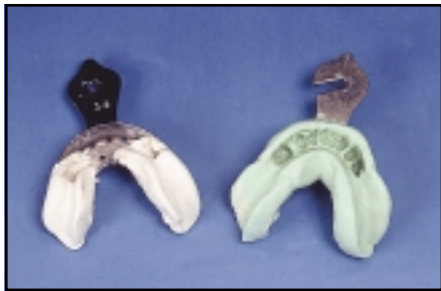

Figure 3. *Left:* the stock tray customized for the patient by recording the edentulous areas in compound. *Right:* the completed primary impression.

The clinician should ensure that the casts are mounted on split casts so that the primary cast can be removed and examined thoroughly before designing the denture(s).

An area of sensible, if not essential, practice is the use of a wax trial insertion stage before recording the definitive impression for a denture with a cobalt-chromium base. This practice has three principal advantages:

- it allows the patient to visualize, and agree to the appearance of, the denture at an early stage of the treatment;
- it enables the clinician to plan paths of insertion and to plan for crown modification, etc.;
- it enables the technician to plan the wax-up of the framework

without compromising aesthetics and denture stability (Figure 5).

Production of Special Trays

Recent studies have indicated that clinicians are less than proficient in prescribing special tray design.^{1,2} Details of special tray prescriptions are available in standard prosthodontic textbooks and will not be addressed here, but basically the spacing should be 2–3 mm on dentate areas (the former for polyethers, polysulphides and polyvinylsiloxanes and the latter for irreversible hydrocolloid impression materials) and 1 mm in edentulous areas.

DEFINITIVE IMPRESSIONS

Once the special trays have been constructed, spaced appropriately for the needs of the impression material, the clinician must record the contours of the remaining teeth, the remainder of the arch and the functional depth and width of the saddle areas.

Accurate reproduction of the remaining dental component is obtained by recording, precisely, the coronal and occlusal aspects of the remaining teeth, including any prepared surfaces. This may be achieved by:

1. Making sure no debris/saliva bubbles are present by blowing dry the surfaces with air from the 3-in-1 syringe.
2. Placing a controlled amount of impression material on the occlusal surfaces.
3. Placing the loaded tray in the mouth.
4. Removing the tray, performing appropriate infection control and ensuring the impression is cast according to the manufacturer's instructions. The problems of sending definitive impressions recorded in irreversible hydrocolloid through the post or by courier are that syneresis/imbibition may result, with consequent distortion of the resultant cast relative to the mouth.

Where peripheral stability is indicated, for example with unilateral or bilateral free-end saddles, the clinician is advised to ensure that the intended saddle area is moulded appropriately. This is achieved by:

- ensuring that the tray is not overextended lingually and buccally;
- moulding the intended saddle area with tracing compound to determine the functional width and depth of the buccal and lingual sulci (Figure 6);
- recording the overall impression using an appropriate impression material.

As no data are available from scientifically based studies to determine if one impression material is superior to another regarding accuracy of fit of dentures, we recommend the combination of a sound impression technique and appropriate pouring of the master cast; the choice of the impression material is essentially one of clinician's preference.

The philosophy of this technique is applicable to conventional dentures or to implant-supported dentures; the principal difference will be that, where implants are being used, impression

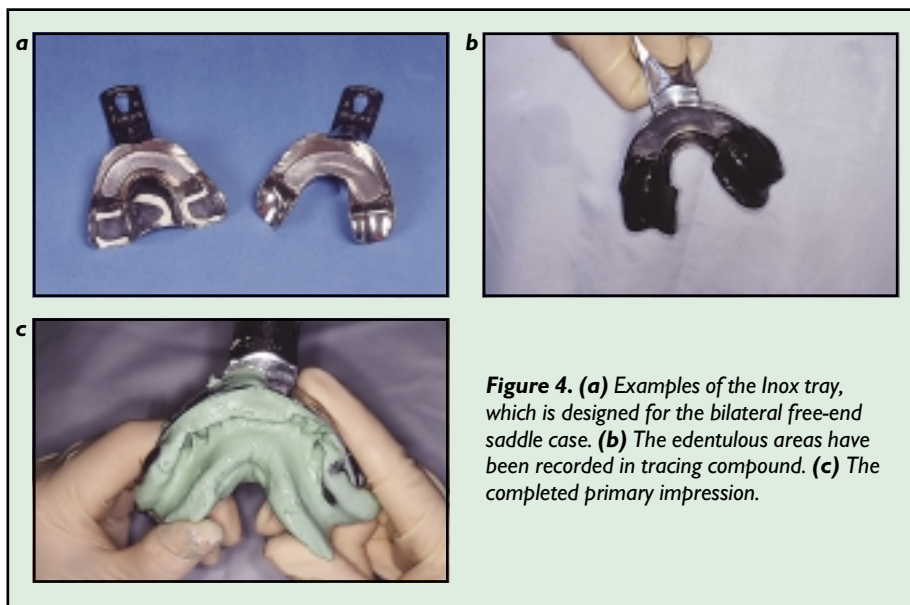


Figure 4. (a) Examples of the Inox tray, which is designed for the bilateral free-end saddle case. (b) The edentulous areas have been recorded in tracing compound. (c) The completed primary impression.

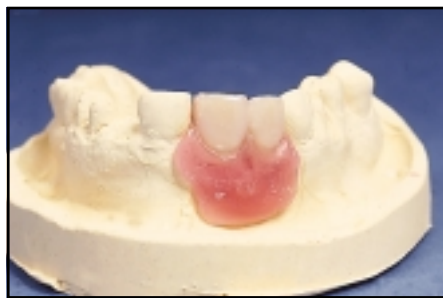

Figure 5. The wax trial denture stage permits a good three-dimensional assessment of where the teeth, and thus the framework, ought to be placed.

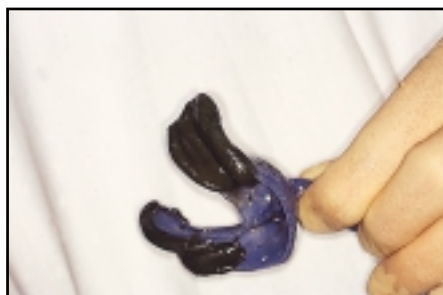


Figure 6. The peripheral roll of the denture may be determined by placing tracing compound on the buccal and lingual aspects of the special tray before recording the definitive impression.

posts and saddle areas have to be recorded (in addition to any remaining teeth).

SPECIAL MODIFYING PROCEDURES

Combination of Fixed and Removable Prosthesis

Typically, the denture should be designed before construction of the fixed prosthesis. This is good practice as the fixed prosthesis may well require guide planes, supporting elements (such as cingulum/occlusal rests or milled shoulders) or precision attachment components as essential components of the denture. Common sense would therefore dictate that the denture design is known by the technician before construction of the fixed component.

When the fit of the fixed component(s) is clinically acceptable, a pick-up impression will be required in

order to make the denture. This may be performed in a 2 mm spaced special tray and will involve the use of any of the common impression materials (we prefer a polyether impression material such as Impregum-soft by ESPE (Morley Street, Loughborough, Leicestershire, UK), because it is more rigid when set than other commonly available impression materials). We recommend recording large saddle areas in tracing compound first to reduce the amount of elastic impression material required. With this pick-up technique the fixed and removable components may be incorporated onto one model, thereby satisfying the technical demands for denture construction (Figure 7).

Dentures Supported by both Teeth and Mucosa

Some dentures are supported by both teeth and mucosa – for example, the Kennedy I, II or IV type denture. A considerable amount of rhetoric has been written (and stated) over whether impressions should be mucostatic or mucodisplasive. To date, no scientifically based clinical trial has compared the two impression types; thus anecdote and clinical preference tend to reign over fact.

The problems of the differing capabilities of periodontal membrane and mucosa to support dentures and the means of addressing them are beyond the scope of this article; however, we will describe here one technique that has been designed to address the clinical problems involved, either at the time of prescribing the denture or perhaps a year or so post-delivery when further alveolar ridge resorption has occurred.

The Altered Cast Technique

In 1954, Applegate³ described an impression technique which catered for both supporting elements, reduced the potential for occlusal errors and facilitated maintenance of the completed partial denture. He called it the Altered Cast Technique and it

includes features as follows:

- Following the assessment of fit of the cast framework, a trial base is placed on the saddle area(s), with 1 mm (one thickness of wax) spacing between the resin base and the soft tissues of the saddle.
- A wash impression is recorded of the saddles. Although Applegate used impression waxes to record the saddle areas, these are not now readily available and light-bodied impression materials could be used instead of the impression waxes. Some clinicians prefer to use GC Iso Functional compound (GC Corporation, Tokyo, Japan). (N.B. In this technique, pressure is placed only on the occlusal rests or other tooth-supported components of the framework, not on the edentulous saddles).
- The master cast is sectioned at the distal end of the last abutment tooth and the framework placed into the teeth of the master cast. The cast is ‘altered’ by pouring stone into the saddle areas and processing the denture on the new saddle base (Figure 8).

RELINIE IMPRESSIONS

Every partial denture, particularly those which are mucosa borne or tooth and mucosa borne, will inevitably lose tissue fit (and possible occlusal contact) because of residual ridge resorption. The clinician should therefore plan for this when considering denture design.⁴



Figure 7. The fixed components were ‘picked-up’ in the polyether impression and a definitive master cast poured. This enabled the wax trial denture to be made appropriately.

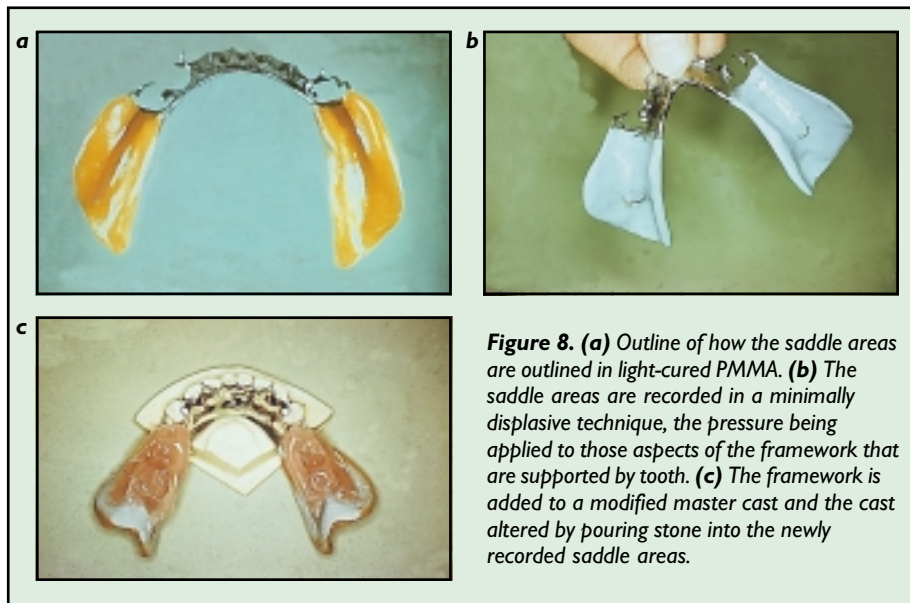


Figure 8. (a) Outline of how the saddle areas are outlined in light-cured PMMA. (b) The saddle areas are recorded in a minimally displasive technique, the pressure being applied to those aspects of the framework that are supported by tooth. (c) The framework is added to a modified master cast and the cast altered by pouring stone into the newly recorded saddle areas.

Basic clinical principles involved for routine reline procedures:

- Assess the case to confirm that a reline is required. Where residual ridge resorption is excessive, where the impression surface of the denture bears no or little resemblance to the denture-bearing mucosa, or if components of the denture are missing, a replacement denture might be a better option.
- Take a reline impression. The technique will depend on whether the denture is supported by teeth alone, mucosa alone or by both teeth and mucosa.

For tooth-borne prostheses, the saddle areas will inevitably, but not exclusively, have a base of dental

casting alloy covered with acrylic resin. This may be recorded via a paste-wash impression or a light or medium-bodied material (after removing some of the resin overlying the framework) and with the teeth lightly in occlusion. When set, an overall impression should be recorded and the denture picked up in the impression. In this way, the resin portion of the base may be relined without fear of loss of fit and with no fear of altering the occlusion (Figure 9).

A similar technique applies in the case of mucosa-borne prostheses.

For the tooth and mucosa-borne prostheses the saddle areas should be relined using a paste-wash impression material or an impression material of light-bodied consistency. With the denture and its reline impression *in situ* an overall impression is recorded as

described above.

Dentures that are tooth and tissue-borne tend to provide the main problems for mandibular removable partial dentures, and Applegate's Altered Cast Technique may be useful in such cases. Some clinicians use a modified Altered Cast Technique and record the minimally displaced saddle areas with softened tracing compound before using the overall pick-up technique.

REFERENCES

1. Basker RM, Harrison A, Davenport JD, Marshall JL. Partial denture designs in general dental practice – 10 years on. *Br Dent J* 1988; **165**: 245–249.
2. Smith PW, Richmond R, McCord JF. The design and use of special trays in prosthodontics: guidelines to improve clinical effectiveness. *Br Dent J* 1999; **187**: 423–426.
3. Applegate OC. *Essentials of Removable Partial Denture Prosthesis*. Philadelphia: WB Saunders, 1954; pp.166–174.
4. Davenport JC, Basker RM, Heath JR, Ralph JP. *Colour Atlas of Removable Partial Dentures*. London: Mosby-Wolfe, 1988.

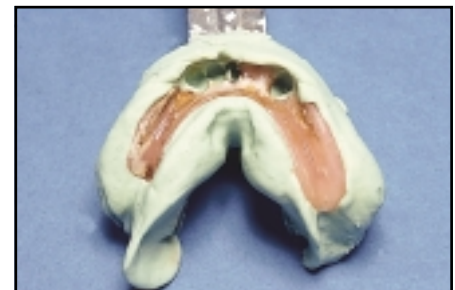

Figure 9. A functional impression of the impression surface of the lower removable partial denture was recorded in Visco-Gel (Dentsply, Germany) and, with the denture *in situ*, an overall impression recorded in an irreversible hydrocolloid impression material.

ABSTRACT

WHY ARE MY CROWNS 'HIGH'?

Assessment of Occlusal Reduction during Preparation of Teeth for Fixed Restorations. C.D. Lynch, R.J. McConnell. *Journal of Prosthetic Dentistry* 2002; **87**: 110–111.

Most journals include a 'helpful hint' section from time to time, and this one is extremely simple yet remarkably effective.

As the authors observe, inadequate tooth removal will result in a restoration which is thin, poorly contoured and liable to fracture or perforate, whilst excessive removal may reduce retention and compromise the pulp.

It is suggested that from time to time during the preparation, the patient occludes into a small sheet of wax, in both central and excursive movements. The wax is removed from the mouth and the resultant indentations measured

with a simple caliper (Iwanson decimal caliper; ASA Dental SpA, Bouzzano, Italy). The thickness is measured accurately and the amount of reduction modified accordingly.

How many high crowns have I adjusted in my career, and how much time would I have saved, and will I save in the future, by this very simple and sensible procedure?

Peter Carrotte
Glasgow Dental School